



VARIATIONS IN THE MIDDLE EAR ANATOMY INTRAOPERATIVELY IN PATIENTS OF CHRONIC OTITIS MEDIA

Dr.Sushil Gaur¹, Dr Shruti Tandon², Dr Abhay Kr Singh³, Umang Lakhera^{4*},
Dr Abhinav Raj⁵

¹Prof, ²SR, ³Associate Prof. ⁴Post Graduate, ⁵ASSIST PROF.

From Dept of ENT, Santosh Medical College and Hospital, Santosh Deemed to be University.

*CORRESPONDING AUTHOR- DR UMANG LAKHERA

ABSTRACT

Introduction: Middle ear is a very complex structure. Hence not only microscope but the use of endoscope is imperative to assess variations in its anatomy. With the same aim we are conducting the study focussing on variations in middle ear anatomy in CSOM patients not only clinico-anatomically but pathologically as well.

Materials and methods: Here we analysed total patient population of 36 of which 25 patients had chronic otitis media mucosal type and other 11 patients had squamosal type.

Observations: Subtle inter-subject variability was found between the patients in squamosal type vs mucosal type CSOM. Most of the patients had inter-subject variability where middle ear ventilation pathway was blocked as cholesteatoma was found near eustachian tube or near tensor fold or eroding various ossicles. Thus, out of 11 squamosal 6 patients had blockade at the level of tensor fold anteriorly of which 4 cases were involving eustachian tube opening anteriorly as well. On the other hand when the middle ear mucosa was noted 5 patients of mucosal disease had congested mucosa while 7 had hypertrophic mucosa but only 3 had mucosa that was edematous.

Conclusion: Thus middle ear ventilation pathway blockade was more a feature of squamosal type CSOM while whereas mucosal type was associated with more clear middle ear ventilation pathways.

Key words: middle ear ventilation pathway, eustachian tube, chronic otitis media, endoscope, middle ear surgery operatively.

INTRODUCTION

The anatomy of middle ear is very complex. The success of tympanoplasty has been studied with different grafts like butterfly graft, temporalis fascia and different techniques like with the use of microscope with or without endoscope. The comparison of sinus tympani morphology has also been done in previous studies. The issue that has not yet been studied much is the variations in involvement of different middle ear region. Hence, we intend to study the same the patients of CSOM undergoing middle ear surgery as assessed by endoscope per

In this study anatomical observations were made of middle ear of all patients having chronic otitis media in dry and safe ear and individual variations were noted endoscopically.

Thus clinico-anatomical and pathological variations in involvement of different middle ear lesions was done

MATERIALS AND METHODS

In this study we used a total patient population of 36 of which 25 patients had chronic otitis media mucosal type and other 11 patients had squamosal type.

Patients were selected from those who were admitted to ENT ward of Santosh Medical College and Hospital,GZB without predilection to any particular sex. Patients that had mild to moderate or even severe hearing loss were included in this study. Extremes of ages were excluded from the study. Patients who were lost during the study or incomplete PTA were excluded from the study.

The surgery were performed by the same surgeon with more or less same surgical techniques. In all surgeries endoscopy was used to see and clear difficult areas of middle ear.

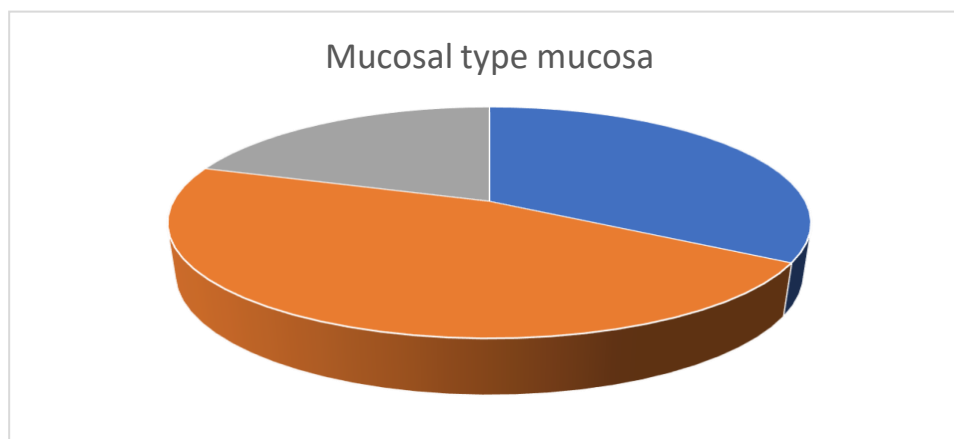
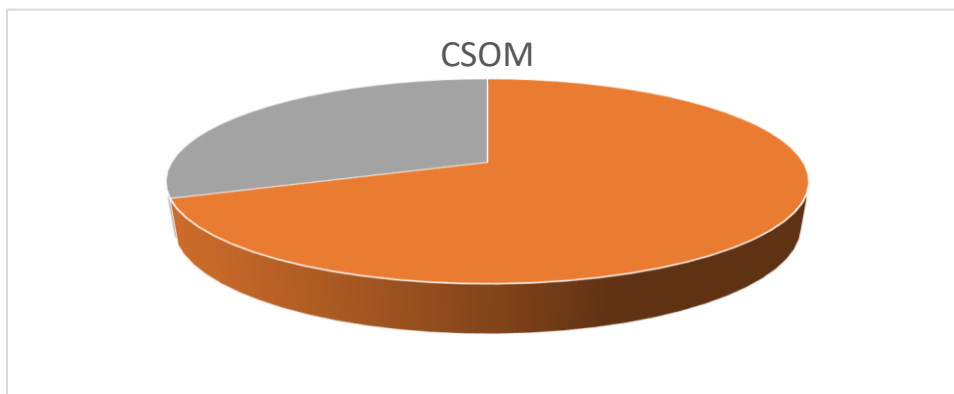
Other types of surgeries like myringoplasty or just tympanoplasty without cholesteatoma related to safe ear or small perforation were excluded from the study.4 mm 30 degree and 0 degree endoscope were uniformly used throughout these cases to assess the anatomy

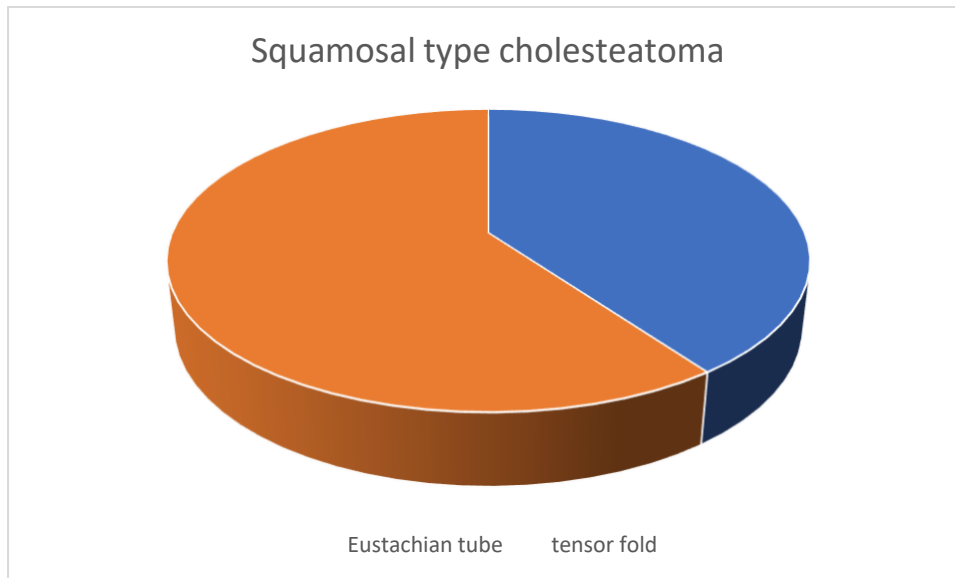
of different areas of the middle ear.

All these patients were examined endoscopically for the differences in their anatomy and comparison were done amongst them. PTA was also done as a mark of severity. The PTA was compared before and after the operation at post op 3 months. Also, the graft uptake rate was performed as assessed on microscopy.

RESULTS

Of 36 total CSOM patients 11 were squamosal while others were mucosal type. Of 11 squamosal common areas of block included eustachian tube orifice and tensor fold which were 4 and 6 respectively. In 25 mucosal type patients where middle ear mucosa was noted 5 patients of mucosal disease had congested mucosa while 7 has hypertrophic mucosa while only 3 had mucosa that was edematous.





DISCUSSION

Middle ear ventilation pathway is carried out properly only when the eustachian tube function is intact. The aeration is carried out through large tympanic isthmus between tensor tympani tendon and posterior incudal ligament. Hence obstruction at this site can lead to impedance in ventilation eventually leading to cholesteatoma formation if not treated.

We studied the patients middle ear anatomy and noted different findings intraoperatively. This was also correlated with mastoid pneumatization and there was definitely one where severity was more when the mastoid was sclerotic. Different areas of invasion of the middle ear by cholesteatoma was thoroughly noted and studied. Common region of blockade in ventilation was found in the area between IS joint and malleus which is was occupied by the cholesteatoma. Of 11 patients about 8 patients were found to have blockade at this site.

Other site of cholesteatoma invasion was tensor fold (Figure 1), eustachian opening anteriorly while long standing cases were found to have the involvement of stapes with or without oval window involvement. To illustrate the same is the following photo taken intraoperatively shows the involvement of stapes as well as oval window as visualised with 30-degree endoscope through the aditus.

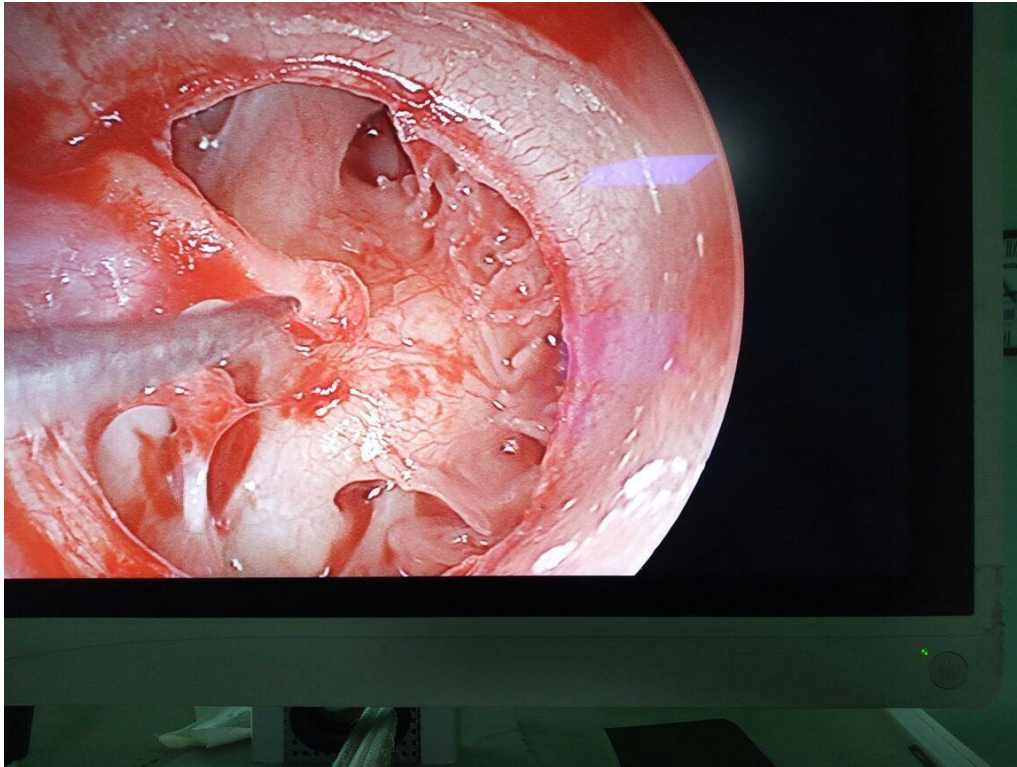


Figure no 1. Patent tensor fold as seen endoscopically.

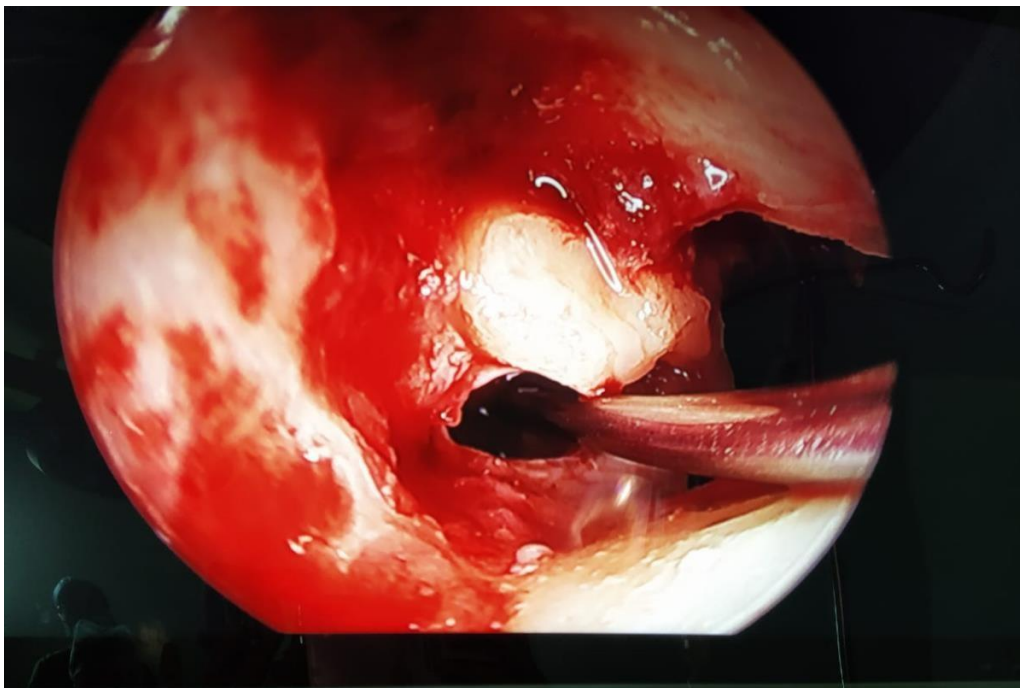


Figure no 2. Clearing the disease from isthmi.

Similarly other variations are noteworthy to mention where out of 11 squamosal 6 patients had blockade at the level of tensor fold anteriorly of which 4 cases were involving eustachian tube opening

anteriorly as well. Of the remaining 5 only two were found to have primary involvement of posterior isthmus (Figure no 2) with ossicular damage.

In 25 cases where no cholesteatoma

was found or in primary mucosal disease of pars tensa the eustachian tube function was found to be normal as seen on endoscopy intraoperatively as well as eustachian tube function tests done preoperatively. This also corresponded well with mastoid pneumatization where all but 5 mucosal disease patients were found to be pneumatic mastoid.

When the middle ear mucosa was noted 5 patients of mucosal disease had congested mucosa while 7 had hypertrophic mucosa but only 3 had mucosa that was edematous. Remaining mucosal disease patients had normal or near normal middle ear mucosa.

CONCLUSION

Thus, in this study we found that when there is obstruction at level of isthmus and disruption in middle ear ventilation pathways that is not treated and longstanding squamous disease is common, seen as pearly white cholesteatoma sac involving different areas of middle ear. In mucosal disease on the other hand, we found less destruction of middle ear anatomical structures as ventilation pathways were more open.

References:

1. Palva T, Ramsay H. Incudal folds and epitympanic aeration. *Am J Otol* 1996;17:700-8
2. Görür K, Özcan C, Talas DU. The computed tomographical and tympanometrical evaluation of mastoid pneumatization and attic blockage in patients with chronic otitis media with effusion. *Int J Pediatr Otorhinolaryngol* 2006;70:481-5.
3. Palva T, Ramsey H, Bohlurg J. Lateral and anterior view to tensor fold and supratubal recess. *Am J Otol* 1998;19:405-14.
4. J. Euben, S. Machiels, N. Mardyla. Middle ear surgery: why and how to switch from microscope to endoscope B-ENT, 2018, 14, 45-51
5. Verma B, Dabholkar Y, Velankar H, and Saberwal H, Use of endoscope as adjunct to microscope in cholesteatoma surgery- A non-randomized, non-controlled study 2017