



Hepatoprotective Activity Of Ethanolic Extract Of *Crinum Asiaticum* Bulbs Against Ccl₄ Induced Hepatotoxicity In Rats

Konepally Vishnu Mohan Reddy^{1*}, S.Suman².

^{1,2}Creative Educational Society's College Of Pharmacy, Department Of Pharmacology, Chinnatekur, Kurnool, Andhra Pradesh, India-518218.

***Corresponding author : S.Suman .**

Creative Educational Society's College Of Pharmacy, Department Of Pharmacology, Chinnatekur, Kurnool, Andhra Pradesh, India-518218. Email : kalyan.suman1985@gmail.com Mobile.N.O:9949521100.

Abstract

Objectives : *Crinum asiaticum* bulbs ethanol extract (EECA) was used to study the hepatoprotective activity against the CCL₄ induced hepatotoxicity in rats .

Method: The hepatoprotective effects of EECA have been studied against carbon tetrachloride (CCl₄) in rats. Individual rats were given EECA doses of 100, 200 and 400 mg/kg (w/w) for 14 days. On day 15, CCl₄ 1.25 ml/kg (ip) induced hepatotoxicity in all rats of all groups. The silymarin (100 mg/kg p.o) administered as standard drug. The effects of EECA on activity ALP, SGOT, SGPT, and BILIRUBIN (direct & total) were determined and histopathological examination of liver sections was also performed.

Result: This extract depletion of ALP, SGOT, SGPT, and BILIRUBIN (direct & total) levels against CCl₄-induced liver injury in rats. Histopathological evidence showed that EECA was highly hepatoprotective at 200 mg/kg and also significantly reduced biochemical liver enzyme levels.

Conclusion: Recent research results clearly demonstrate that EECA has hepatoprotective effects against CCl₄ induced hepatotoxicity in rats .

Keywords:- *Crinum Asiaticum* ,Hepatoprotective, HepatoToxicity ,Carbon Tetrachloride, Silymarin.

CPCSEA Re.No: 1305/Po/Re/S//09/CPCSEA.

INTRODUCTION :

The liver is one of the major organs involved in drug and toxin metabolism [1,2] play a central role in the kinetics of absorption, distribution and excretion. Most drugs and some active or inactive metabolites. When the liver is exposed to toxic chemicals, contaminants cause the formation of reactive oxygen species (ROS) associated with cellular necrosis and many other diseases that increase lipid peroxidation and depletion in tissues GSH level [3].

CCl₄ is one of the most important and widely used hepatotoxicants in experimental studies of liver disease. In the liver, CCl₄ is converted into two free radicals. Cytochrome-mediated trichloromethyl radical (CCl₃) and proxy trichloromethyl radical (OCCl₃) P450. It can cause severe liver damage such as fatty changes, centrilobular steatosis, inflammation, apoptosis, cell necrosis [4, 5]. Therefore, the main intercellular structure is cell membranes, endoplasmic reticulum, mitochondria, etc. are affected by CCl₄ [6]. Enzymes are produced when the cell membrane of liver cells is damaged. It is released into the circulation [7] and increases tissue lipid peroxidation, oxidative stress, etc. serum levels of many biochemical markers such as transaminases, alkaline phosphatase, bilirubin, triglycerides, and cholesterol [8].

Bioactive compounds of medicinal plants played an important role in coping with liver diseases induced by oxidative stress are not currently envisioned and thus may be a promising strategy. Develop drugs that are effective against these diseases. Many studies have shown that plants antioxidant extracts protect against CCl₄-induced hepatotoxicity by inhibiting them. Enhancement of lipid peroxidation and antioxidant enzyme activity [9-19].

Crinum asiaticum, commonly known as poisonous bulbs belongs to the Amaryllidaceae family and is used in traditional medicine to reduce inflammation and symptoms, and to treat osteoarthritis [20]. Phytochemical study on the presence of glycosides, alkaloids and flavonoid pigments in the bulbs of *Crinum asiaticum*. The bulbs contain alkaloids notably licorin and crinamine. *Crinum asiaticum* plant having anti-inflammatory, antioxidant, anti-microbial, anti-diabetic, anti-ulcer, anti-viral activity

Some medicines in Indian healthcare system (Ayurveda) is used as an effective hepatoprotectant. Because some medicinal preparations and medicinal plants are mentioned in Ayurveda, it has been studied for the treatment of various liver diseases. [21,22] Experts from each department regarding our literature research. This plant has been reported to

have various biological activities. Reports on hepatoprotective activity have not yet been published of *Crinum asiaticum*. Therefore, in this study, an attempt was made To assess the hepatoprotective activity profile of *Crinum asiaticum* against carbon tetrachloride (CCl₄) induced Hepatotoxicity in rats.

MATERIALS AND METHODS :

Plant Material:

The *Crinum asiaticum* plant was collected from the hills of Tirumala, Andhra Pradesh, India and authenticated by Prof. Dr. K. Madhava Chetty, Assistant Professor, Department of Botany, Sri Venkateshwara University, Tirupati. The whole plant was dried in shade; bulbs were separated and pulverised to get a coarse powder. (**Voucher Number :2011**)

Extraction :

Powdered *Crinum asiaticum* bulbs was sieved (0.2 mm), then the powder was placed in a thimble and subjected to single solvent extraction using a Soxhlet apparatus. Solvents are chosen in order of increasing polarity. Petroleum ether, diethyl ether, chloroform, ethanol, and water. The raw material bulbs (*Crinum asiaticum*) was used at a ratio of (1:3). That is, 1 part powder material, 3 parts solvent. The extraction process was carried out until a colorless solvent was obtained. The evaporated extract was stored in a desiccator.

Experimental Animals :

This study was conducted after receiving an institutional animal ethics Committee approval number (IAEC/CESCP/2023-05). albino wistar rats were used in the study. Animals were obtained from CES College of Pharmacy, Chinnatekur, Kurnool. Animals were housed in polyacrylic cages Maintained at standard conditions of 18°C + 2°C for 12 hours light-dark cycle. Animals have free access to a standard chow diet and water ad libitum.

Acute toxicity studies :

Acute toxicity testing complies with Organization for Economic Co-operation and Development Guideline 423. [23] Ethanol extracts from *Crinum asiaticum* bulbs have been found to be safe up to 2000 mg/kg body weight by Orally. After 72 hours the animals were found to be well tolerated. There were no death and no sign of lethal toxicity. Therefore, one tenth of the dose was chosen for this hepatoprotective study. Therefore, three dose levels were selected for this study: 100 mg/kg (low dose), 200 mg/kg (medium dose), and 400 mg/kg (high dose).

HEPATOPROTECTIVESTUDY

CCl₄ Induced Hepatotoxicity:

Liver toxicity was induced in rats by administering CCl₄ subcutaneously in a suspension of liquid paraffin (LP: CCL₄=1:2v/v) at a dose of 1ml per kg body weight.

Experimental Design:

Thirty six (36) healthy rats of either male or female were divided into six (6) experimental groups (n= 6 per group). Separate cages were allotted for each group and the cages were marked with the group number (I-VI). The groups were as follows:

- **Group 1 (Normal):** Normal group receives water.
- **Group 2 (Control):** Serves as a disease control receives carbon tetra chloride on 15th day (CCL₄ 1.25ml/kg .ip)
- **Group 3 (Standard):**Serves as standard receives silymarin at a dose of (**100 mg/kg /p.o**)for 14 days on 15th day receives carbon tetra chloride (CCL₄ 1.25 ml /kg /i.p).
- **Group 4(Test drug):** Receives low dose (**100mg/kg/p.o**) of bulbs of crinum asiaticum ethanolic extract for 14 DAY ,on 15th day receives carbon tetra chloride (CCL₄ 1.25 ml /kg / i.p)
- **Group5 Test drug):** Receives medium dose (**200mg/kg/p.o**) of bulbs of crinum asiaticum ethanolic extract for 14 days ,on 15th day receives carbon tetra chloride (CCL₄ 1.25 ml /kg /i.p)
- **Group 6 (Test drug):** Receives high dose (**400 mg/kg/ p.o**) of bulbs of crinum asiaticum ethanolic extract for 14 day , on 15th receives carbon tetra chloride (CCL₄ 1.22 ml/kg / i.p)
- CCl₄ administered in a suspension of liquid paraffin (1:2v/v) at a dose of 1ml per kg body weight. All the drugs administered via subcutaneous route for a 15th day.
- After 24 hours of the treatment protocol blood was gathered by retro-orbital plexus from all animals.
- Collected blood samples are allowed to clot and centrifuged at 3000rpm for 10 minutes and serum was separated.

ESTIMATION OF LIVER FUNCTION MARKERS

- The serum levels of marked enzymes viz. ALP, SGOT, SGPT, and BILURUBIN (direct& total) were measured by using semi auto analyzer.
- All enzymes estimations are assayed using biochemical kits.

HISTO PATHOLOGICAL STUDIES:

The liver of each rat was excised and preserved after dissection 10% formalin. Liver tissue was removed from each

lobe were taken and possessed For paraffin embedding in standard microtechnology. Sections of Make 5–6 mm and stain with hematoxylin and eosin stain For microscopy observed. The histopathological changes were clearly evaluated.

STATISTICAL ANALYSIS:

Data were presented as mean \pm SEM. Statistical significance Differences between groups were assessed using one-way ANOVA followed by Dunnett's test multiple comparison analysis using GraphPad Prism 5 software. The Considered statistically significant at $p < 0.001$, $p < 0.01$, and $p < 0.05$.

RESULTS :

Table 2 :Phytochemical screening :

| S.NO | TEST | INFERENCES |
|------|--------------------|------------|
| 1 | Alkaloids | + |
| 2 | Glycosides | + |
| 3 | Phenolic Compounds | + |
| 4 | Terpenoids | + |
| 5 | Tannins | + |
| 6 | Flavonoids | + |

Effect of EECA on Biochemical Liver Enzyme Levels :

Effect of *crinum asiaticum* bulbs ethanol extract on biochemical parameters Carbon tetrachloride-induced hepatotoxic rats. Rats treated with CCl_4 Liver damage was developed and observed in the form of elevated liver serum levels Enzymes such as ALP, SGOT, SGPT, and BILURUBIN (direct & total) compared to normal controls. After pretreatment with silymarin, the ethanol extract was found to be good Protection against CCl_4 -induced hepatotoxicity. significant reduction of Serum enzyme levels were elevated in extract-treated animals compared to Toxic control animals, as seen in Table 2.

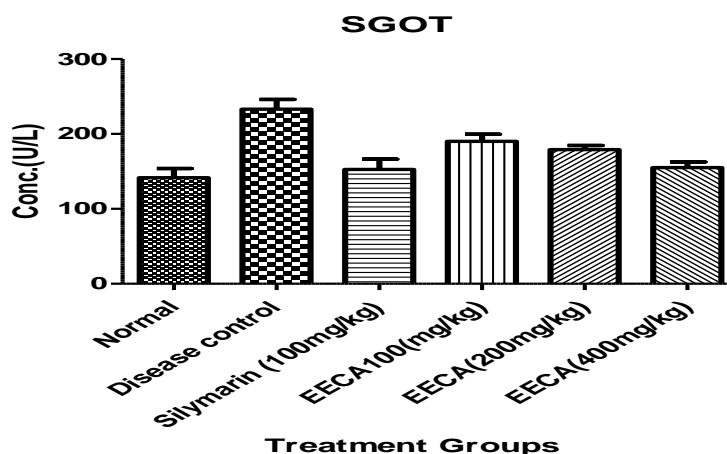
Table 2: Effect of EECA on biochemical liver enzymes against CCl_4 induced hepatotoxicity in rats

| Groups | Treatment | SGOT/AST (U/L) | SGPT/ALT (U/L) | ALP (U/L) | TOTAL BILIRUBIN (mg/dl) | DIRECT BILIRUBIN (mg/dl) |
|--------|-------------------------------------------|----------------------------------|-----------------------------------|-----------------------------------|----------------------------------|----------------------------------|
| I | Normal | 141.1 \pm 21.71 | 85.00 \pm 4.397 | 127.94 \pm 4.113 | 0.9760 \pm 0.007 | 1.272 \pm 0.003 |
| II | Disease Control [CCl_4 1 ml/kg] | 231.8 \pm 31.30 ^{###} | 245.74 \pm 0.478 ^{###} | 250.5 \pm 0.381 ^{###} | 1.850 \pm 0.006 ^{###} | 3.940 \pm 0.009 ^{###} |
| III | Standar [Silymarin (100 mg/kg P.O.)] | 152.0 \pm 29.27 ^{***} | 146.22 \pm 0.268 ^{***} | 132.20 \pm 0.383 ^{***} | 1.200 \pm 0.007 ^{***} | 1.507 \pm 0.006 ^{***} |
| IV | EECA (100 mg/kg P.O.) | 190.0 \pm 3.704 [*] | 210.08 \pm 0.502 [*] | 211.36 \pm 0.962 [*] | 1.400 \pm 0.003 [*] | 2.713 \pm 0.004 [*] |
| V | EECA (200 mg/kg P.O.) | 179.8 \pm 3.238 ^{**} | 201.43 \pm 0.983 ^{**} | 195.08 \pm 1.704 ^{**} | 1.325 \pm 0.015 ^{**} | 2.390 \pm 0.002 ^{**} |
| VI | EECA (400 mg/kg P.O.) | 155.5 \pm 5.27 ^{***} | 160.65 \pm 0.620 ^{***} | 153.35 \pm 1.075 ^{***} | 1.253 \pm 0.003 ^{***} | 1.520 \pm 0.004 ^{***} |

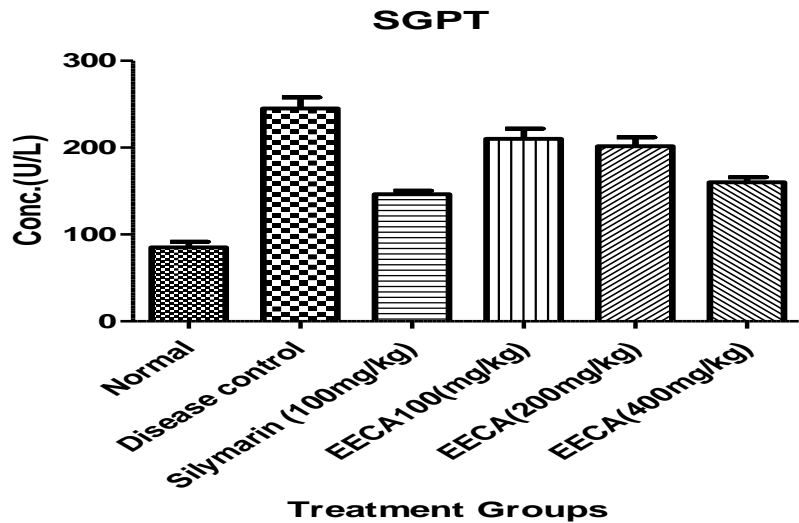
All values are expressed as mean \pm S.E.M for six rats in each group. Comparisons made between ^{###} $p < 0.001$, ^{##} $p < 0.01$, [#] $p < 0.05$; Normal VS Disease control, ^{***} $p < 0.001$, ^{**} $p < 0.01$, ^{*} $p < 0.05$ Disease control Vs Treatment: One-way ANOVA followed by Dunnett's -t test.

Effect Of Ethanolic Extract Of EECA On Biochemical Liver Enzymes Against CCl_4 Induced Hepatotoxicity In Rats

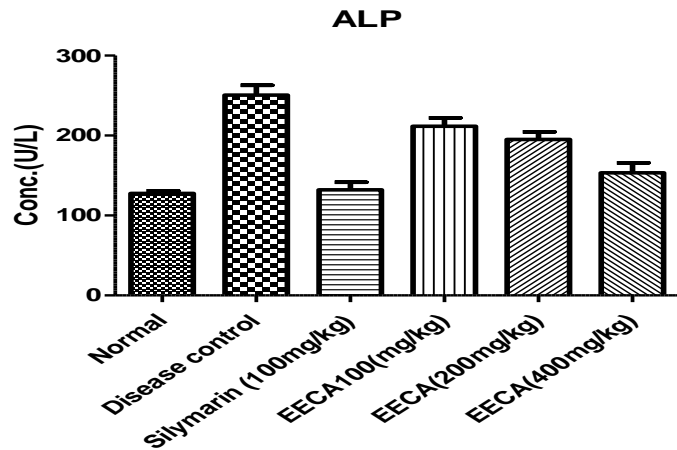
Graph 1 :Estimation Of SGOT



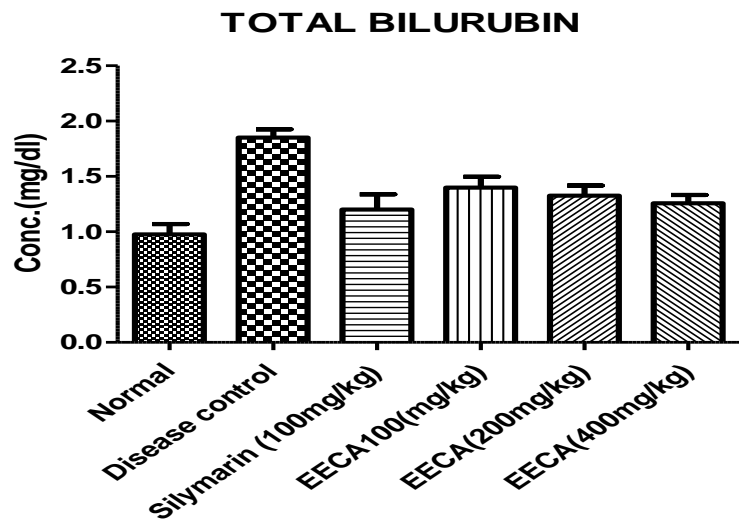
Graph2: Estimation Of SGPT

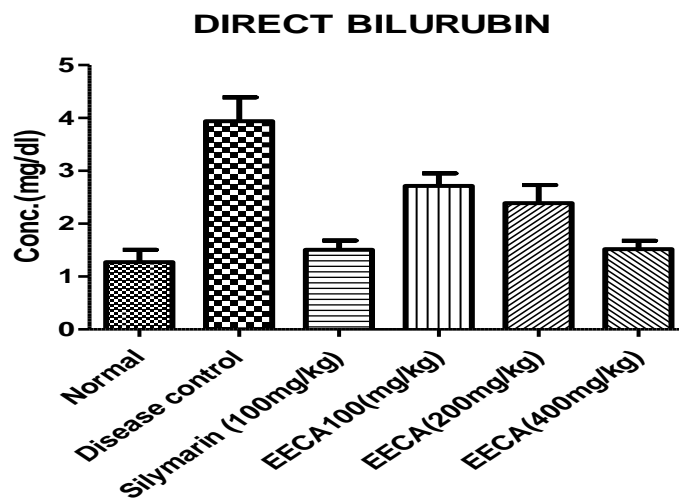
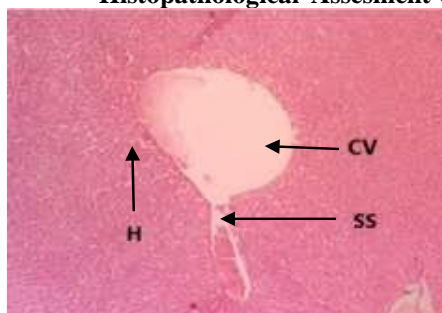


Graph 3: Estimation Of ALP

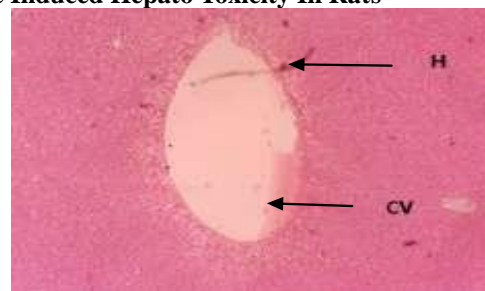


Graph 4: Estimation Of Total Bilurubin

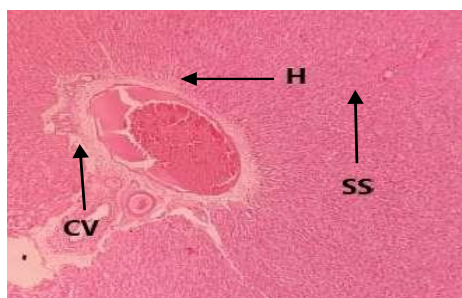


Graph 5: Estimation Of Direct Bilurubin**Histopathological Assesment Of Carbon Chloride Induced Hepato Toxicity In Rats**

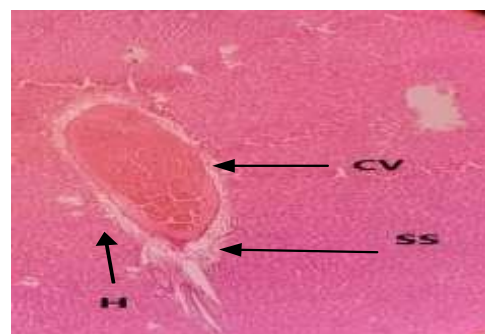(A) Normal



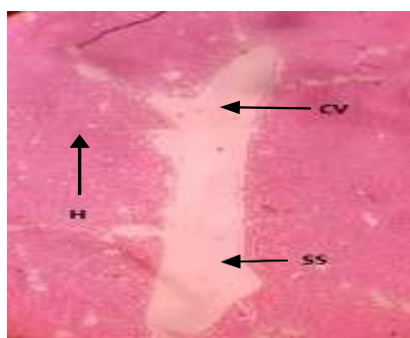
(B) DiseaseControl



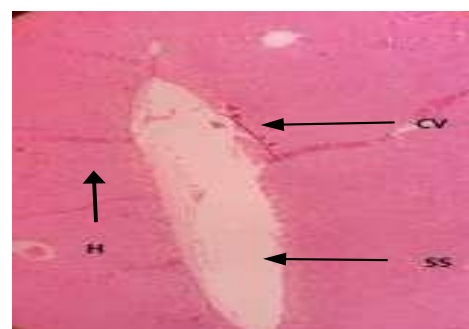C.Silymarin(100mg/kg)



(D) EECA(100mg/kg)



(E)EECA (200mg/kg)



(F) EECA(400mg/kg)

DISCUSSION :

EFFECT OF EECA ON BIOCHEMICAL ENZYME LEVELS:

SGOT, SGPT, ALP, TOTAL BILIRUBIN, DIRECT BILIRUBIN:

The effects of EECA on ALP, SGOT, SGPT, and BILIRUBIN (direct & total) are shown in Table 1. Serum levels were increased in the CCl₄-treated group compared to the normal group ($p < 0.001$). Serum levels of EECA 100 mg/kg, 200 mg/kg, 400 mg/kg treatment groups and silymarin treatment group were significantly suppressed, respectively, compared to the disease control group.

Histopathological impact of EECA:

Histopathological examination of CCl₄-treated rats revealed fatty degeneration, necrosis, and fibrosis (fig B) compared to the normal group (fig A). Co-administration of EECA preserved the histological structure of the liver, but there was minimal hepatic tissue congestion and regeneration of liver as shown in the (fig. F).

CONCLUSION :

This study demonstrates that EECA has potent hepatoprotective effects against carbon tetrachloride-induced hepatotoxicity in rats. Phytochemical analysis revealed the presence of alkaloids, glycosides, flavonoids, tannins and phenols. Our results indicate that the hepatoprotective effects of EECA in its 400 mg/kg dose compared to 200 mg/kg and 100 mg/kg are clearly due to its flavonoid, tannin, phenolic and antioxidant properties. It indicates that there is the same has been demonstrated by histopathological evaluation of CCl₄. Therefore, it can be concluded that the Bulbs of *Crinum asiaticum* ethanolic extract can effectively suppress CCl₄-induced hepatotoxicity in rats, suggesting a possible protective function in various liver diseases. Further research is needed to isolate and characterize the EECA active substance responsible for hepatoprotective activity and to elucidate its mechanism of action.

ACKNOWLEDGEMENT:

This work was Carried out by Creative Educational Society's College of Pharmacy, Kurnool, Andhra Pradesh.

CONFLICT OF INTEREST:

We declare that we have no conflict of interest.

REFERENCES:

1. Sahreen, S.; Khan, M. R.; Khan, R. A. Hepatoprotective Effects of Methanol Extract of *Carissa Opaca* Leaves on CCl₄-Induced Damage in Rat. *BMC Complement. Altern. Med.* 2011, 11, 1–9, <https://doi.org/10.1186/1472-6882-11-48>.
2. Salama, A. F.; Tousson, E.; Elfetoh, E. M.; Elhaak, M.; Elawni, M. Effect of Egyptian Plant *Silybum Marianum* on the Kidney during the Treatment of Liver Fibrosis in Female Albino Rats Induced by Alcohol in Comparison to the Medical Silymarin from China. *Int J Curr Microbiol Appl Sci* 2015, 4, 557–570.
3. Cheng, N.; Ren, N.; Gao, H.; Lei, X.; Zheng, J.; Cao, W. Antioxidant and Hepatoprotective Effects of *Schisandra Chinensis* Pollen Extract on CCl₄-Induced Acute Liver Damage in Mice. *Food Chem. Toxicol.* 2013, 55, 234–240, <https://doi.org/10.1016/j.fct.2012.11.022>.
4. Weber, L. W.; Boll, M.; Stampfl, A. Hepatotoxicity and Mechanism of Action of Haloalkanes: Carbon Tetrachloride as a Toxicological Model. *Crit. Rev. Toxicol.* 2003, 33, 105–136. <https://doi.org/10.1080/713611034>.
5. Heibatollah, S.; Reza, N. M.; Izadpanah, G.; Sohailla, S. Hepatoprotective Effect of *Cichorium Intybus* on CCl₄-Induced Liver Damage in Rats. *Afr. J. Biochem. Res.* 2008, 2, 141–144.
6. Reynolds, E. S. Liver Parenchymal Cell Injury: I. Initial Alterations of the Cell Following Poisoning with Carbon Tetrachloride. *J. Cell Biol.* 1963, 19, 139–157, <https://doi.org/10.1083/jcb.19.1.139>.
7. Cullen, J. M. Mechanistic Classification of Liver Injury. *Toxicol. Pathol.* 2005, 33, 6–8, <https://doi.org/10.1080/01926230590522428>.
8. Shanmugam, G.; Ayyavu, M.; Rao, D. M.; Devarajan, T.; Subramaniam, G. Hepatoprotective Effect of *Caralluma Umbellata* against Acetaminophen Induced Oxidative Stress and Liver Damage in Rat. *J. Pharm. Res.* 2013, 6, 342–345, <https://doi.org/10.1016/j.jopr.2013.03.009>.
9. Dhiman, A.; Nanda, A.; Ahmad, S. A Recent Update in Research on the Antihepatotoxic Potential of Medicinal Plants. *Zhong Xi Yi Jie He Xue Bao* 2012, 10, 117–127, <https://doi.org/10.3736/jcim20120201>.
10. Duh, P.-D.; Lin, S.-L.; Wu, S.-C. Hepatoprotection of *Graptopetalum Paraguayense* E. Walther on CCl₄-Induced Liver Damage and Inflammation. *J. Ethnopharmacol.* 2011, 134, 379–385, <https://doi.org/10.1016/j.jep.2010.12.029>.
11. Kuo, D.-H.; Kang, W.-H.; Shieh, P.-C.; Chen, F.-A.; Chang, C.-D.; Tsai, M.-L.; Cheng, A.-C.; Ho, C.-T.; Pan, M.-H. Protective Effect of *Pracparatum Mungo* Extract on Carbon Tetrachloride-Induced Hepatotoxicity in Rats. *Food Chem.* 2010, 123, 1007–1012, <https://doi.org/10.1016/j.foodchem.2010.05.052>.
12. Quan, T.; Fisher, G. J. Role of Age-Associated Alterations of the Dermal Extracellular Matrix Microenvironment in Human Skin Aging: A Mini-Review. *Gerontology* 2015, 61, 427–434, <https://doi.org/10.1159/000371708>.
13. Shahjahan, M.; Sabitha, K. E.; Jainu, M.; Devi, C. S. Effect of *Solanum Trilobatum* against Carbon Tetra Chloride

- Induced Hepatic Damage in Albino Rats. *Indian J. Med. Res.* 2004, 120, 194–198.
14. Sheweita, S. A.; Khoshhal, K. I.; Baghdadi, H. H. Osteoporosis and Oxidative Stress – Role of Antioxidants. In *Systems Biology of Free Radicals and Antioxidants*; Laher, I., Ed.; Springer: Berlin, Heidelberg, 2014; 2973–2995, https://doi.org/10.1007/978-3-642-30018-9_128.
 15. Vuda, M.; D'Souza, R.; Upadhyay, S.; Kumar, V.; Rao, N.; Kumar, V.; Boillat, C.; Mungli, P. Hepatoprotective and Antioxidant Activity of Aqueous Extract of *Hybanthus Enneaspermus* against CCl₄- Induced Liver Injury in Rats. *Exp. Toxicol. Pathol.* 2012, 64, 855–859, <https://doi.org/10.1016/j.etp.2011.03.006>.
 16. Madhavan, S. A. Hepatoprotective and Antidiabetic Effect of Aqueous Extract of *Costus Spicatus* Jacq. Rhizome Extract in Streptozotocin Induced Diabetic Rats–Histological Study. 2021.
 17. Gupta, A.; Kumar, R.; Ganguly, R.; Singh, A. K.; Rana, H. K.; Pandey, A. K. Antioxidant, Anti-Inflammatory and Hepatoprotective Activities of *Terminalia Bellirica* and Its Bioactive Component Ellagic Acid against Diclofenac Induced Oxidative Stress and Hepatotoxicity. *Toxicol. Rep.* 2021, 8, 44–52, <https://doi.org/10.1016/j.toxrep.2020.12.010>.
 18. Benny, N. R.; Sonia, N. S.; Sreekala, G. S. Hepatoprotective Medicinal Plants Traditional Knowledge to Scientific Evidences: A Review. *J. Pharmacogn. Phytochem.* 2021, 10, 285–288.
 19. Fortis-Barrera, M. de los Á.; Alarcón-Aguilar, F. J.; Becerril-García, A.; Flores-Sáenz, J. L. E.; AlmanzaPérez, J. C.; García-Lorenzana, M.; Lazzarini-Lechuga, R. C.; Román-Ramos, R.; Blancas-Flores, G. Mechanism of the Hypoglycemic Activity and Hepatoprotective Effect of the Aqueous Extract of *Cecropia Obtusifolia* Bertol. *J. Med. Food* 2020, 23, 783–792, <https://doi.org/10.1089/jmf.2019.0126>.
 20. https://en.wikipedia.org/wiki/Crinum_asiaticum
 21. Kshirsagar AD, Mohite R, Aggrawal AS, Suralkar UR. Hepatoprotective medicinal plants of Ayurveda-A review. *Asian J Pharm Clin Res.* 2011;4(3):1-8. 13.
 22. Shaik A, Elumalai A, Eswaraiah MC, Usha. An updated review on hepatoprotective medicinal plants. *J Drug Deliv Ther.* 2012;2(2):1-3
 23. OECD: Guidelines,423, Acuteoraltoxicity: environmental health and safety monographserieson testing and assessmentno. Environmental directorate.2000.