



Management of Congenitally Missing Lateral Incisors using dental implants – an orthodontic perspective

Tina Chugh¹, Abhay Kumar Jain², Nishita Garg³, Rajiv Ahluwalia¹

¹Orthodontics and Dentofacial Orthopedics, Santosh Dental College, Santosh deemed to be University, Ghaziabad, Uttar Pradesh, India.

²Orthodontics and Dentofacial Orthopedics, Hazaribag College of Dental Science, Hazaribag, Jharkhand, India.

³Pedodontics and preventive dentistry, Dental institute, RIMS, Ranchi, Jharkhand, India.

Corresponding author: Dr. Tina Chugh

Abstract

Several treatment alternatives exist for the replacement of congenitally missing lateral incisors. These include canine substitution, fixed partial dentures, and single tooth implants. Implant restorations are gaining popularity for the replacement of missing teeth. The central incisor and canine often erupt in less-than-optimal positions, and frequently require preprosthetic orthodontic treatment to create sufficient space for implant placement. This article discusses various aspects of orthodontic treatment required for implant restoration.

Keywords: dental implants; incisor; orthodontics

Introduction

The successful use of dental implants to replace missing teeth has been one of the most “exciting and evolving areas of clinical dentistry”¹ While implants have expanded restorative treatment options, treatment planning has become more complex for the dental practitioner, and an interdisciplinary team approach is recommended to achieve an excellent, esthetic result for a more predictable outcome.²⁻⁴ It may involve preprosthetic orthodontic treatment following consultations with an oral surgeon or a periodontist and restorative dentist to ensure orthodontic alignment which will facilitate the surgical, implant and restorative treatment. The present article discusses various aspects of orthodontic treatment required for implant restoration of congenitally missing permanent lateral incisors.

Orthodontic Treatment Planning

The permanent maxillary lateral incisor is one of the most common congenitally missing tooth.⁵ The possibility of missing permanent maxillary lateral incisors should be immediately investigated whenever there is asymmetric loss of primary teeth, over-retention of deciduous lateral incisors and canines, impacted maxillary canines or family history of congenitally missing teeth, because of higher association of congenitally missing or peg-shaped lateral incisors with these anomalies.^{6,7} Treatment alternatives for restoring edentulous spaces resulting from congenitally missing laterals include removable partial dentures, conventional fixed bridges, resin-bonded bridges, cantilevered fixed partial dentures, autotransplantation, orthodontic repositioning of canines to close the edentulous space, and single-tooth

implant.⁸ A full set of orthodontic records including radiographs, models and clinical photographs are recommended for the diagnosis of congenitally missing laterals and treatment planning. A diagnostic wax set-up is also beneficial for forecasting various treatment options and to visualize the esthetics.^{7,9} In cases where the occlusion and esthetics of the canine in the lateral position are acceptable, closure of the lateral space by orthodontic treatment may be the simplest alternative treatment option. The benefits of space closure over prosthetic replacement depend on the specific occlusion as well as the morphology and esthetics of the canine. Closing the space usually requires reshaping the substituted teeth as needed for aesthetics.¹⁰ Placement of fixed bridges and dental implants may both require preprosthetic orthodontic treatment to achieve sufficient space. Advantage of using dental implants over fixed bridges is that they do not necessitate “alteration” or “removal” of parts of the natural dentition and are thus considered as the most conservative prosthodontic option for replacing missing lateral incisors.^{8,9} They also maintain the alveolar ridge, enhance occlusal function and provide optimal esthetics.¹¹ When planning for the placement of single-tooth implant, both the quantity and quality of alveolar bone must be assessed before implant placement.¹² There should be a minimum of 6.0 mm of facial-lingual bone and 10 mm of incisogingival bone in order to support a standard implant. In patients who have over-retained primary lateral incisors or canines, keeping the primary tooth as long as possible should be considered to preserve the supporting alveolar bone for future implants. In cases where there is insufficient alveolar bone for implant placement, ridge augmentation

may be necessary in addition to orthodontic repositioning of adjacent teeth.¹³ When quality of bone is considered, Type I, II and III bone offer good strength. Type IV bone with thin cortex and poor medullary strength with low trabeculae density, has been found to be associated with excessive fixture loss.¹⁴ Adequate space should be present between adjacent roots for the placement of implant. The average dental implant fixture is 3.75 mm wide, and 1 to 2 mm of space is necessary between the fixture and the adjacent roots.¹² Therefore, minimum 6-8 mm of bone is required between the roots of maxillary central incisor and canine. The roots of both these teeth should be parallel to slightly divergent to avoid complications resulting from root proximity. Usually, the tip of permanent maxillary central incisor is approximately 4 degrees while that of the permanent maxillary canine is 8 degrees as per MBT prescription¹⁵, which means that the roots are slightly divergent. Bending of archwire or bonding a contralateral bracket on a central incisor (such as placing the maxillary right central incisor bracket on the maxillary left central incisor) can further accentuate root divergence in the implant area.⁴ Space for the coronal restoration must also be assessed. The average implant platform, which is 4mm wide, requires a space of 1 mm mesially and distally between the platform and the adjacent tooth to facilitate proper healing and the development of a papilla postoperatively.¹³ Thus, a minimum of 6 mm of space is required for placement of permanent maxillary lateral incisor crown. As a rule, the mesiodistal width of permanent maxillary lateral incisors should be 80% of the mesiodistal width of the permanent maxillary central incisor.¹⁶ However, if the patient is missing

only one permanent maxillary lateral incisor, the space required is primarily dictated by the width of the contralateral maxillary lateral incisor to achieve symmetrical esthetics and occlusion. When both permanent lateral incisors are congenitally absent, the occlusion may influence the amount of space required for the implant restoration and the proportional relationship between the central and lateral incisors.¹³

After placing the implants (Phase I), an acrylic denture tooth with a bonded bracket can be ligated to the archwire to maintain the space and improve esthetics. At the end of Phase I, healing abutments are placed with minimal invasive surgery. The provisional abutments can be inserted and prefabricated provisional polycarbonate crowns can be cemented with temporary cement to form a provisional restoration over the abutment. After finishing minor corrections, the fixed appliances can be removed. Provisional restoration over abutment is continued until the final prosthesis is made. Removable vacuum-form retainers containing bonded acrylic denture teeth are also acceptable in the interim as they prevent relapse in all three dimensions.¹⁷ However, caution should be taken when using vacuum-form retainers with respect to the occlusion especially when only one arch has been treated orthodontically as open bite, anterior and posterior, may be created as this type of full coverage retainer may allow selective teeth to overerupt and thus create more orthodontic problems. The prosthetic teeth should be contoured to avoid impinging on the alveolar gingiva. It is important not to impinge on the tissue mesial and distal to the pontic, because this area will become the papilla after implant placement. When considering implants as the treatment to

replace missing teeth, the age of the patient is of paramount importance. The optimal time for placement of implants is after the growth of the maxilla, mandible and alveolus is completed. If implants are placed before growth is complete, the surrounding alveolar bone may continue to develop vertically and adjacent teeth may continue to erupt. Thus a discrepancy between the gingival margins of the implant and the natural teeth is created and the implant appears to be submerged. This creates a functional as well as an esthetic problem. The growth status of patient can be evaluated using hand wrist radiographs, by superimposition of sequential cephalometric radiographs and growth charts. For males, completion of facial growth, which often corresponds to general growth, may not occur until the age of 21 years; in young women, growth may be completed by age of 15 years. If growth is complete, dental implants can be placed as soon as the edentulous space has been created and the tissues have stabilized following orthodontic treatment.¹³ This clinical report describes an interdisciplinary approach for the treatment of a patient diagnosed with congenitally missing permanent maxillary lateral incisors.

Case description

An 18 year old male patient reported with the chief complaint of spacing between upper front teeth. Intraoral and orthopantogram (OPG) examinations revealed congenitally missing permanent maxillary lateral incisor and mandibular lower central incisors, and over-retained deciduous mandibular central incisors (Fig 1 A, B, C and 2). Midline diastema of 2 mm was present. The maxillary canines had drifted mesially and were in an end-on relation with their mandibular counterpart

with an Angle's Class I molar relation bilaterally. After thorough clinical and radiographic examinations, patient was informed about the treatment alternatives. Patient did not prefer to use removable prosthesis because of his age and the resultant poor esthetics. Also, a three unit fixed partial denture option was not accepted by him as he was not willing to undergo a preparatory treatment for the supporting teeth. Therefore, an implant-supported fixed prosthesis for missing maxillary lateral incisors was opted as the preferred treatment modality. As there was insufficient space for the implant placement, the patient was informed about fixed orthodontic treatment for creating space for implant placement (Figure 1 A). The aim of the treatment was to orthodontically create space for the replacement of missing lateral incisor, retract the canines to achieve Class I canine relation and closure of midline diastema. Secondly it was decided to prosthetically replace the missing lateral incisors with oral implants. Patient was not willing for extraction of over-retained deciduous mandibular incisors, so they were left untouched.

In upper and lower arches, teeth were bonded and banded. Leveling and alignment was achieved using sequential 0.016" nickel titanium wire (NITI[®],Ormco, Glendora, Calif) followed by 0.018" round stainless steel wires (A.J. Wilcock,Whittlesea, Victoria, Australia)in the upper arch over a period of 3 months. The canines were distalized on 0.019" X 0.025" stainless steel (Dentaurum, Pforzheim, Germany) rectangular wire using NiTi open coil spring (Sentalloy[™], GAC International, Central Islip, New York) to achieve Class I canine relation. In doing so, sufficient amount of space was

achieved for replacement of missing lateral incisor and the upper midline diastema was closed. Once sufficient space was created (Fig 3A and B), the patient was subjected to implant placement surgery. Under local anesthesia, a labial 2-sided full-thickness flap was reflected with relieving incisions on the mesial side of the canines and distal side of left and right maxillary central incisors (Figure 4). It was observed that insufficient bone was present for insertion of the selected implant dimensions. So, an autogenous bone graft was harvested from chin region and was placed in lateral incisor area. Two Xive implants (13 mm length, 3.0 mm diameter, Denstply–Friadent Co., Mannheim, Germany) were placed in the congenitally missing maxillary lateral incisors area (Figure 4). Multiple 4-0 polyglactin sutures were used to accomplish primary closure after the placement of cover screws. Patient received the following postoperative medication: 1000 mg amoxicillin clavulanic acid twice daily, 275 mg naproxen sodium two times daily and chlorhexidine 0.2% mouth rinse three times daily. The sutures were removed after 7 days. Follow-up and maintenance examinations were provided at two and half to threemonths interval during osseointegration phase. During this period, lateral incisor pontics were placed for maintaining spaces and for esthetics. At the end of this period, healing abutments were placed with minimal invasive surgery (Figure 5). Prefabricated provisional polycarbonate crowns were selected and relined with self-curing acrylic resin to form a provisional restoration over the abutment and were cemented with temporary cement. The provisional restorations conditioned soft tissues to generate scalloped contours during four weeks. The minor corrections were

completed, and fixed appliances were removed. Then for definitive restorations implant level impressions were made. The full ceramic crowns were fabricated and were ultrasonically cleaned in distilled water for ten minutes. The crowns' marginal fit and occlusion were also assessed intraorally before being resin-cement adhered to the abutments. The patient was pleased with the result and was motivated to maintain his oral hygiene (Figure 6 and 7 A, B, C). The patient was recalled at 1 week, 1 month, 6 months and 12 months postoperatively for evaluating the clinical parameters- such as periodontal index and radiographical examinations.

Discussion

An aesthetic treatment plan is crucial for maxillary lateral incisors that are congenitally absent. To enhance the prosthesis's biological, cosmetic, and functional outcomes, further preprosthetic surgical operations like bone or soft tissue regeneration are frequently required. The patient's expectations for treatment must be satisfied, and the benefits and drawbacks of practicable treatments must be reviewed. Congenitally absent maxillary lateral incisor restoration treatments include canine replacement, single tooth implants, resin-bonded fixed partial dentures, removable partial dentures, and tooth-supported restorations.⁸

When choosing the best course of action for each unique instance, the space circumstances, patient age, and the patient's dental, skeletal, and occlusal issues should all be taken into account. The patient must be involved in the treatment strategy.

Clinical significance

Implant supported prosthesis are the most conservative way of treatment because of

protection of the supported teeth, prevention of the alveolar bone resorption and its esthetic outcome.^{8,9} In this case report, the patient was evaluated both radiographically and clinically at each appointment. At both implant sites, there was no evidence of bone or soft tissue loss.

Conclusion

For a successful outcome, a coordinated orthodontic, prosthodontic, periodontic, and restorative treatment, with careful consideration of patient expectations and requests, are critical. Implant-supported restorations should represent the treatment of choice for the replacement of congenitally missing upper lateral incisors.

References

1. Mantzikos T, Shamus I. Case report: forced eruption and implant site development. *Angle Orthod*1996; 68(2):179-86.
2. Schweizer CM, Schlegel AK, Rudzki-Janson I. Endosseous dental implants in orthodontic therapy. *Int Dent J* 1996; 46(2):61-8.
3. Phillips K, Kois J. Aesthetic peri-implant site development - The restorative connection. *Dent Clin North Am* 1998; 42(1):57-70.
4. Dialogue. The role of the orthodontist on the maxillary anterior implant team. *Am Assoc Orthod*1998;10(2).
5. Proffit WR, Fields HW, Sarver DM. *Contemporary orthodontics*. 4th ed. St. Louis, MO: Mosby Inc.; 2007.
6. Millar BJ, Taylor NG. Lateral thinking: the management of missing upper lateral incisors. *Br Dent J* 1995; 79(3):99-106.
7. Bishara SE. Impacted maxillary canines: a review. *Am J Orthod*

- Dentofacial Orthop 1992; 101(2):159-71.
8. Rupp RP, Dillehay JK, Squire CF. Orthodontics, prosthodontics, and periodontics: a multidisciplinary approach. *Gen Dent* 1997; 45(3):286-9.
 9. Cronin RJ, Cagna DR. An update on fixed prosthodontics. *J Am Dent Assoc* 1997; 128(4):425- 36.
 10. McNeill RW, Joondeph DR. Congenitally absent maxillary lateral incisors: treatment planning considerations. *Angle Orthod.* 1973;43:24-29.
 11. Millar BJ, Taylor NG. Lateral thinking: the management of missing upper lateral incisors. *Br Dent J* 1995; 79(3):99-106.
 12. Shroff B, Siegel SM, Feldman S, Siegel SC. Combined orthodontic and prosthetic therapy. Special considerations. *Dent Clin North Am* 1996; 40(4):911-43.
 13. Spear FM, Mathews DM, Kokich VG. Interdisciplinary management of single-tooth implants. *SeminOrthod*1997; 3(1):45-72.
 14. Jaffin RA, Berman CL. The excessive loss of Branemark fixtures in type IV bone: a 5-year analysis. *J Periodontol.* 1991;62:2-4.
 15. McLaughlin RP, Bennett JC, Trevisi HJ. *Systemized Orthodontic Treatment Planning.* St Louis, Mo: CV Mosby Co;2001:41, 284.
 16. Ong MA, Wang HL, Smith FN. Interrelationship between periodontics and adult orthodontics. *J Clin Periodontol*1998; 25(4):271-7.
 17. Kokich V. Esthetics and anterior tooth position: an orthodontic perspective. Part III: Mesiolateral relationships. *J Esthetic Dent* 1993;5(5):200-7.

Figures

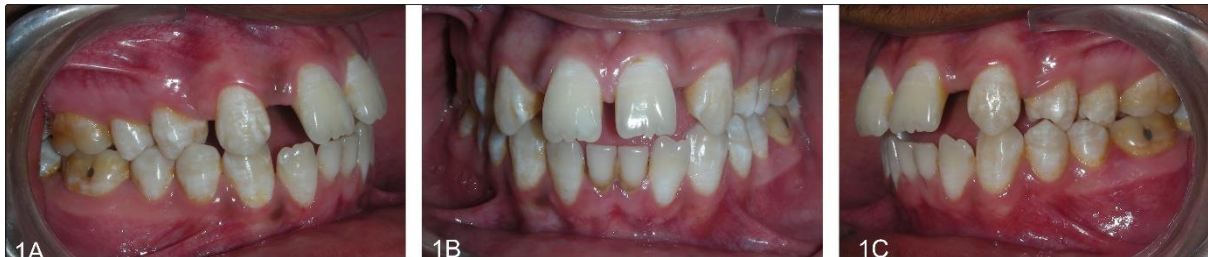

Figure 1 A, B and C: Pretreatment intraoral photographs showing missing permanent maxillary lateral incisors and retained mandibular deciduous central incisors

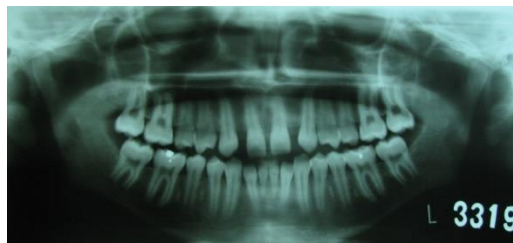


Figure 2: OPG showing missing mandibular central incisors and insufficient space between roots of maxillary central incisors and canine for implant placement

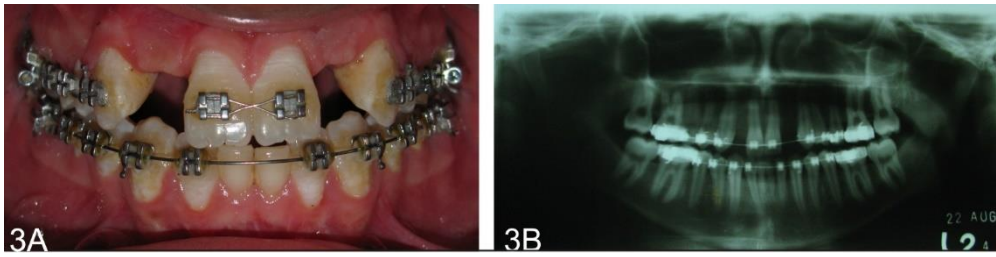


Figure 3 A and B: Intraoral photographs and OPG after creating spaces for implant placement

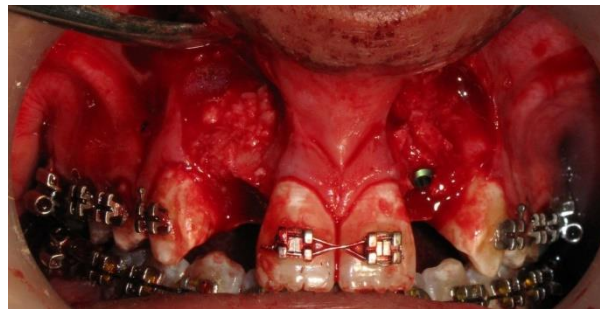


Figure 4: full-thickness flap raised. Bone graft and implants placed.

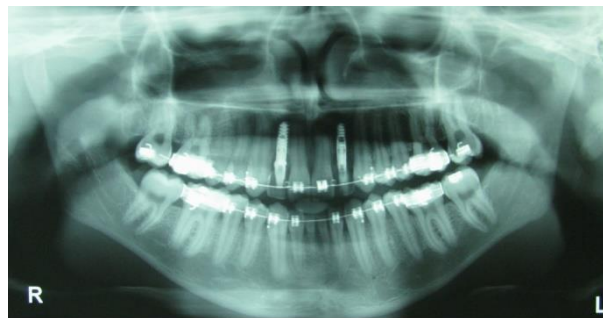


Figure 5: OPG after placement of dental implants

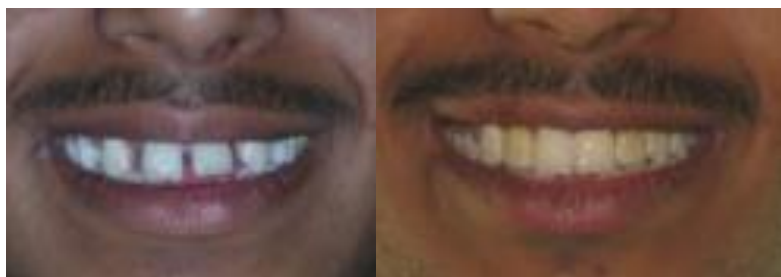


Figure 6: Pre- and post-treatment smile photographs

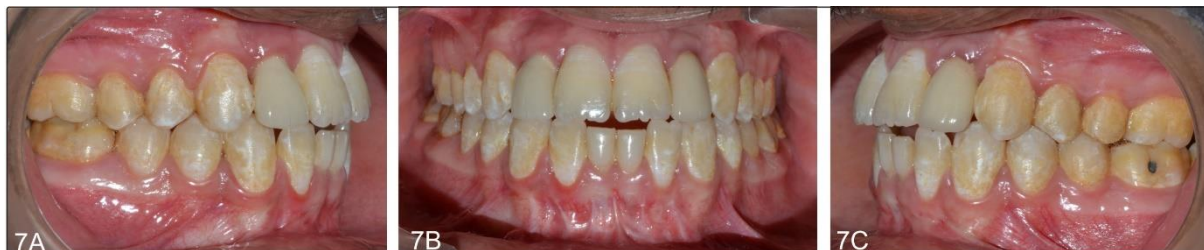

Figure 7 A, B and C: Intra oral view - 1 month follow up