



# Intruded tooth: To treat or not to treat- *A case report*

<sup>1</sup>Dr. Aruna Nautiyal, <sup>2</sup>Dr. Neeti Mittal, <sup>3</sup>Dr. Kajal

<sup>1</sup>Senior lecturer, Department of Periodontology and Oral Implantology, Santosh Deemed to be university.

<sup>2</sup>Professor, Department of Pedodontics, Santosh Deemed to be university.

<sup>3</sup>Postgraduate student, Department of Periodontology and Oral Implantology, Santosh Deemed to be university.

Corresponding author: Dr. Neeti Mittal

## ABSTRACT

Traumatic dental injuries that cause orofacial trauma and result in fractures, displaced, or lost teeth are common in children and young adults. The child's physical, mental, and functional well-being can all be seriously harmed by these. Due to the possibility of causing damage to the periodontal ligament, pulp, and alveolar bone, intrusive luxation of teeth is regarded as one of the most severe forms of dental trauma. It causes axial impacts on the maxillary and mandibular teeth. This article presents a case report of a traumatic intrusive tooth and its subsequent spontaneous eruption.

**KEYWORD:** Intrusion, Intrusive luxation, Re-eruption, Trauma

## INTRODUCTION:

Children frequently experience dentoalveolar trauma, which is a condition that necessitates prompt medical attention not only because of the potential severity of the injury but also because it can cause emotional distress for both the child and the parents.<sup>1</sup> According to a review of the literature, 25% of children who attend school experience dental trauma at some point, with crown fractures occurring most frequently in the permanent dentition and luxation injuries occurring more frequently in the primary dentition. A fall is the most common cause of permanent tooth damage, followed by traffic accidents, violence, and sports.<sup>2</sup>

The axial displacement of the tooth into the alveolus is referred to as intrusive luxation. The damage is the result of an axial impact

to the tooth, in which the energy released forces the tooth into the alveolar process, causing extensive periodontal damage, including tearing and compression, as well as possible crushing or severance of the neurovascular bundle supplying the pulp, which typically results in a more or less severe crown fracture.<sup>3</sup>

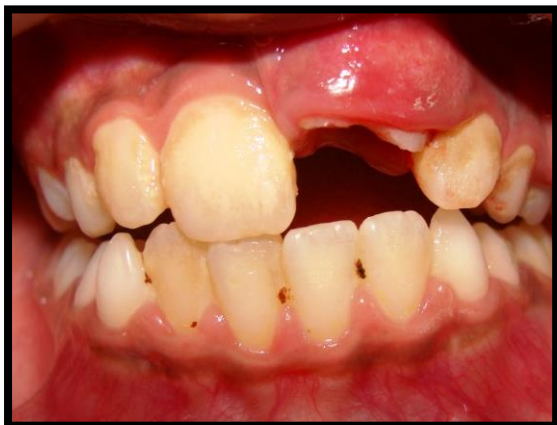Intruded teeth can be divided into three groups based on the amount of clinical displacement: mild intrusion (< 3 mm), moderate intrusion (3-6 mm), and severe intrusion (> 6 mm).

Only 0.5 to 2% of traumas that affect the permanent dentition result in intrusive luxation of permanent teeth. A fall that causes axial impacts on the maxillary and mandibular teeth is the most common cause of intrusive injury to permanent teeth, affecting children between the ages of 6 and

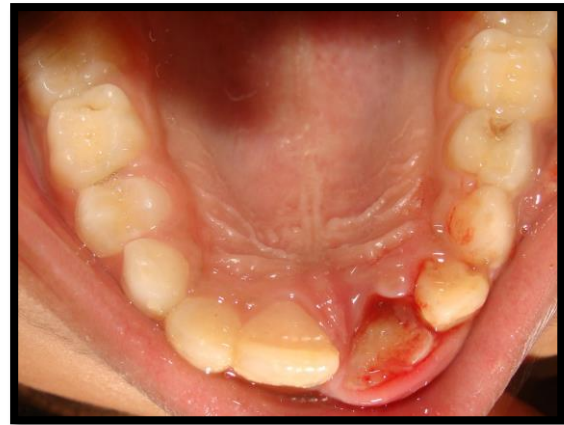12.<sup>4</sup> Root resorption and marginal bone breakdown have both been observed when the pulp is injured, as well as pulpal necrosis and stopped root formation in cases of incomplete root formation when the pulp is injured.<sup>3</sup> Due to the difficulty and rarity of intrusive luxation injuries in permanent teeth, the healing process is complicated and the prognosis is uncertain. After a traumatic intrusion, normal periodontal and pulp healing may occur despite these negative side effects.<sup>5</sup>

#### **CASE REPORT:**

A 12-year-old boy was brought to the outpatient department by his parents with the chief complaint of swelling and fracture of upper left front tooth due to a fall in the playground. The parents of the patient reported to the hospital within half an hour of injury. On extra-oral examination shows no abnormality was detected. Intra-oral examination revealed swelling in relation to the labial mucosa of 21. The concerned tooth (21) presented with Ellis type II fracture, no mobility and the entire coronal portion of the tooth was embedded in the socket which coincided with the diagnosis of severe intrusion (Figure 1 & Figure 2).

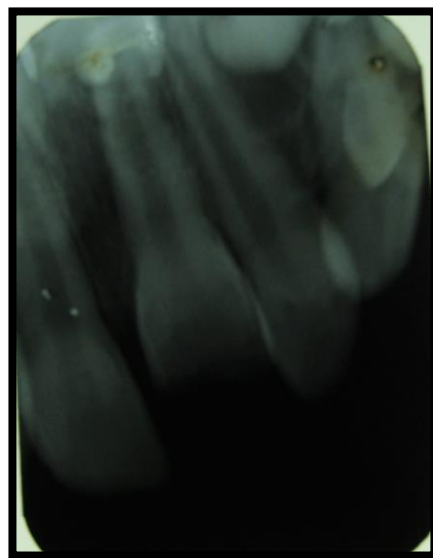


**Figure 1: Swelling in labial mucosa of 21**



**Figure 2: Coronal portion of 21 embedded in the socket**

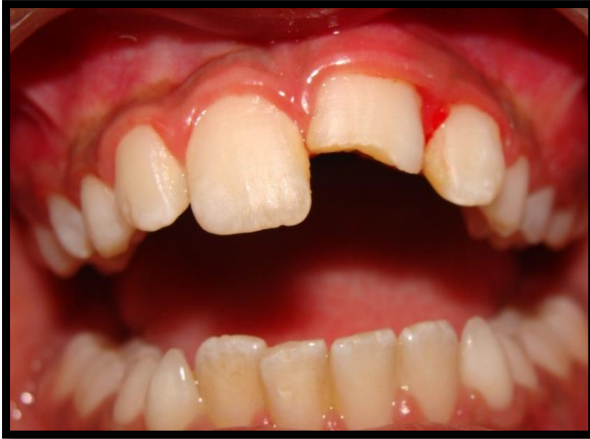For Radiographic evaluation, IOPA (intra-oral periapical radiography) was done with respect to 11 and 21. IOPA revealed incomplete apex formation in relation to 21 with a normal periodontal ligament space.



**Figure 3: IOPA irt 11, 21**

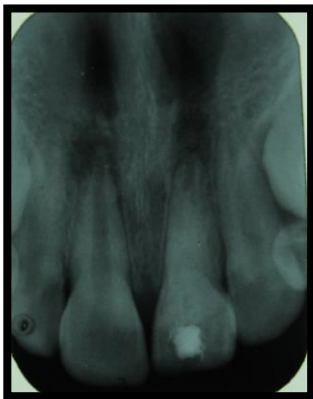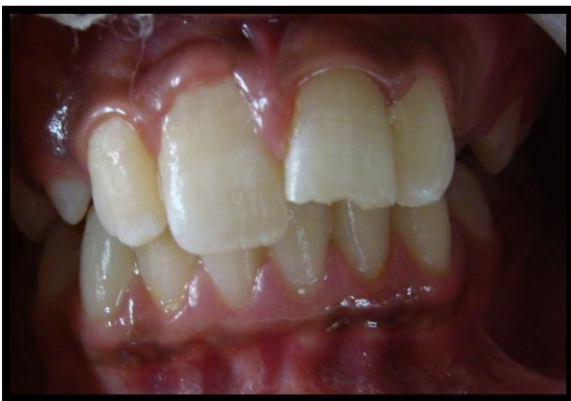After a thorough clinical and radiographical examination, it was decided that for the management of this particular case, a wait and watch approach would be the most appropriate with an intent for spontaneous eruption. The patient was meanwhile advised gingival massage in the concerned area. Patient reported to us after 4 weeks for a follow up visit and it was observed that

1/3rd of the tooth was erupted in the oral cavity (Figure 4).



**Figure 4: 4 weeks after trauma**

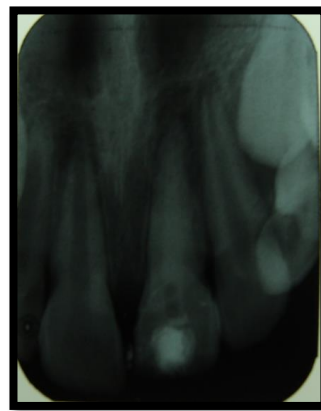
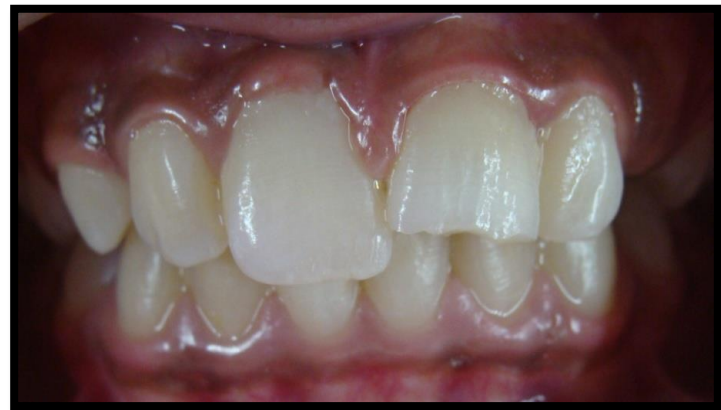Once 8 weeks had elapsed after trauma, it was observed that the tooth had erupted 2/3rd into the oral cavity, calcium hydroxide was then pushed into the periapical area and the patient was recalled for a follow up visit. (Figure 5a & 5b)



**Figure 5a: 8 weeks after trauma**

**Figure 5b: IOPA after 8 weeks**

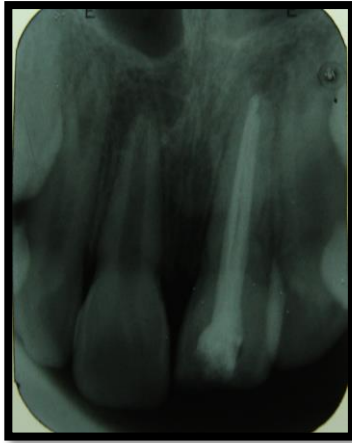Once 16 weeks after trauma had elapsed, it was observed that the tooth had spontaneously erupted into the oral cavity without the need of any surgical/orthodontic intervention. Calcium hydroxide was yet again re-pushed in the fully erupted tooth (21). (Figure 6a & 6b)



**Figure 6a: 16 weeks after trauma**

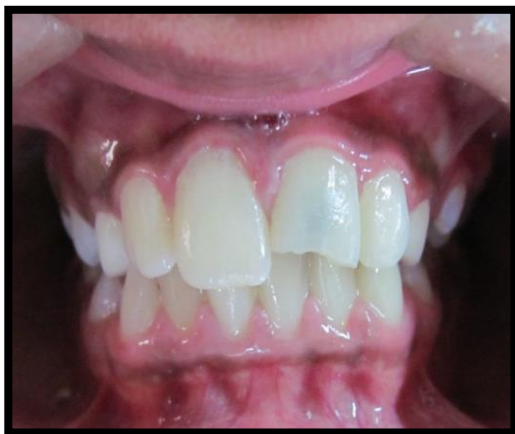**Figure 6b: IOPA after 16 weeks**

This was followed by apexification and obturation was done with respect to 21(Figure 7).



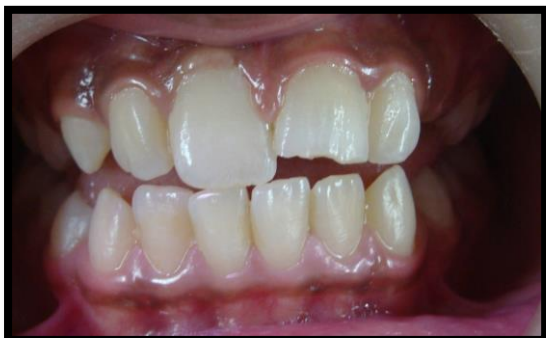**Figure 7: Apexification and obturation irt 21**

The patient did not come for further follow up appointments and reported to our clinic after 11 months with discoloration in relation to 21. (Figure 8)



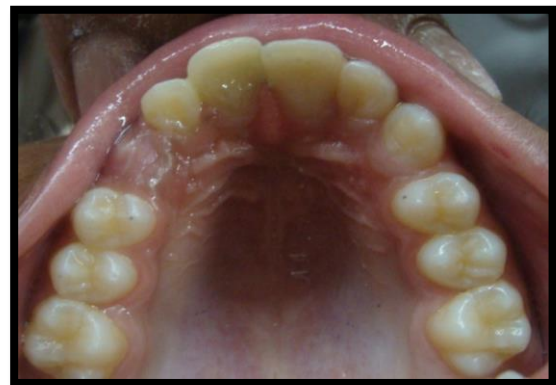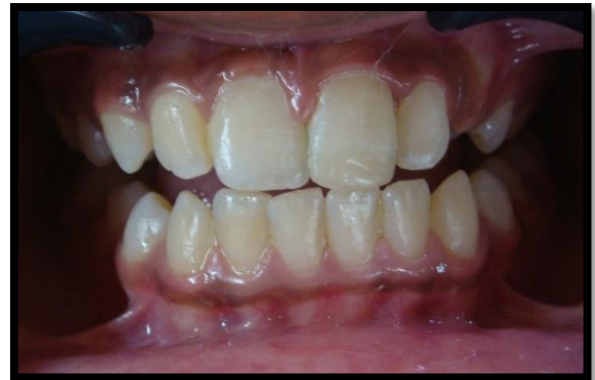**Figure 8: Discoloration irt 21**

A Walking bleach procedure with the application of sodium perborate and 30% hydrogen peroxide was performed to treat the discoloration. (Figure 9)



**Figure 9: Bleaching is done irt 21**

The tooth was then finally restored with respect to 21 for aesthetic purposes. (Figure 12a &12b).



**Figure 12a: post-operative (labial)**

**Figure 12b: Post-operative (Occlusal view)**

#### **DISCUSSION:**

The maxillary anterior teeth are the most frequently affected by dental trauma in children, with tooth intrusion occurring most frequently in children aged 6 to 12 years old.<sup>6</sup> Typically, tooth intrusion involves a single dental component. Injuries due to falls, sports, violence, and traffic accidents are all common etiologic causes.<sup>7,8</sup> In most cases, an intrusion of 1 to 8 mm is observed. Depending on the type of tooth, status of root development (open or closed) degree of displacement, and future prognosis, some treatment options include surgical repositioning, orthodontic

extrusion, waiting for spontaneous eruption, or extraction.<sup>9</sup>

### CONCLUSION:

With regular follow-ups and proper observation, severe intrusive luxation can also be treated without any orthodontic or surgical procedure in an open root apex tooth.

### REFERENCES:

1. Lee JY, Divaris K. Hidden consequences of dental trauma: the social and psychological effects. *Pediatr Dent*. 2009 Mar-Apr;31(2):96-101.
2. Glendor U. Epidemiology of traumatic dental injuries--a 12 year review of the literature. *Dent Traumatol*. 2008 Dec;24(6):603-11. doi: 10.1111/j.1600-9657.2008.00696.x. PMID: 19021651.
3. Andreasen JO, Andreasen FM, Andersson L. Textbook and color atlas of traumatic injuries to the teeth. 4th ed. Oxford UK: Wiley-Blackwell; 2007.
4. Andreasen JO, Bakland LK, Matras RC, Andreasen FM. Traumatic intrusion of permanent teeth. Part 1. An epidemiological study of 216 intruded permanent teeth. *Dent Traumatol*. 2006 Apr;22(2):83-9.
5. Andreasen JO, Bakland LK, Andreasen FM. Traumatic intrusion of permanent teeth. Part 3. A clinical study of the effect of treatment variables such as treatment delay, method of repositioning, type of splint, length of splinting and antibiotics on 140 teeth. *Dent Traumatol*. 2006 Apr;22(2):99-111.
6. Altun C, Cehreli ZC, Güven G, Acikel C. Traumatic intrusion of primary teeth and its effects on the permanent successors: a clinical follow-up study. *Oral Surg Oral Med Oral Pathol Oral Radiol Endod*. 2009 Apr;107(4):493-8.
7. Andreasen JO. Etiology and pathogenesis of traumatic dental injuries. A clinical study of 1,298 cases. *Scand J Dent Res*. 1970;78(4):329-42.
8. Borum MK, Andreasen JO. Therapeutic and economic implications of traumatic dental injuries in Denmark: an estimate based on 7549 patients treated at a major trauma centre. *Int J Paediatr Dent*. 2001 Jul;11(4):249-58.
9. Cunha RF, Pugliesi DM, Correa MG, Assuit DM. Early treatment of an intruded primary tooth: a case report. *J Clin Pediatr Dent*. 2001 Spring;25(3):199-202.